

Full Length Research Paper

Accumulation and Toxicity of Extra Iron Fed as Fumarate in Rabbits

Turki M. Al-Shaikh

Department of Biological Sciences, Faculty of Science, Northern Border University, Arar, Saudi Arabia
E-mail: turkialsheika@hotmail.com

Accepted 18 October, 2012

Deficiency of Iron (anemia) is a common feature of many targets of human living in developing world. For this respect this work was designed to evaluate the daily iron supplementation in treatment of certain types of anemia due to severe shortage of food as well as the study of the fate of excess iron supplementation within the bodies' as chronic iron-overload promotes oxidative stress and organ failure. Three groups of rabbits, one as control, the second severely starved and the third was well fed. The last two groups were both supplemented by iron (as Fumarate tablets) equivalent to those of anemic human therapies, daily till three weeks. The signs of anemic animals were developed in those starved ones such as weakness and size loss, out look and the organs were pale due to the shortage of blood supply. The hepatic and renal cells seemed to be empty with clear cytoplasm and some of the cells were being degenerated. After daily supplementation of iron the structures of the organs were restored to normal, however, certain amounts of iron accumulations were observed. The well-fed group appeared to be normal with excess iron accumulation in the form of stainable granules in a dose – dependent manner. It is easy to say that iron is important supplement to overcome certain type of anemia by daily doses to a limited time. This supplement, if increased, will accumulate and adverse the biological mode of cells and cause a significant hepatotoxic and nephrotoxic effects. Excess oral iron intake should be avoided unless prescribed by a physician.

Keywords: Excess iron supplementation- Iron toxicity- Histopathology- Rabbits

INTRODUCTION

Iron deficiency and anemia are prevalent among infants, children, and women in all ages, and adult men in whom parasites induce blood losses, in developing and even in the industrial world (Hallberg *et al.*, 1995 and WHO; 1992, 1999). This implies that iron supplements are needed across the life span. Prusak and Grzegorzewska (2002) summarized the factors leading to absolute iron deficiency. This factors are, 1) loss of iron as a result of blood loss by gastrointestinal tract, 2) enhanced use of iron during intensive erythropoiesis, 3) dietary iron deficiency or impaired iron uptake from gastrointestinal tract, 4) other forms of gastrointestinal tract impairment,

5) pharmaceutical substances forming in absorbable iron complexes and/or diluting the acidity of gastric juice, 6) certain demographic factors. However, iron supplementation remains an important strategy for the prevention and treatment of iron deficiency anemia and can produce substantial improvement in the functional performance of iron deficient individuals (Allen, 2002). In this review, the adverse effects on iron deficiency anemia increases the risk of both child and maternal mortality that iron deficiency anemia impairs work productivity and child development.

In a report published by Allen (2001) to explained how

anemia and / or iron deficiency could cause low birth weight and preterm delivery. Anemia (by causing hypoxia) and iron deficiency (by causing increase neither serum nor epinephrine concentrations) can induce maternal and fetal stress, which stimulates the synthesis of corticotrophin releasing hormone, intern, a major risk factor for preterm labor. This hormone also increases fetal cortisol production; the cortisol may inhibit longitudinal growth of fetus. Iron deficiency increases oxidative damage to erythrocyte and fetoplacental unit, and also increases the risk of maternal infection.

Iron is both an essential nutrient and a potential toxicant to cells, it requires a highly sophisticated and complex set of regulatory approaches to meet the demands of cells as well as prevent excess accumulation (Beard, 2001). The normal total circulating iron pool is 3 to 4 mg (Ponka *et al.*, 1998); iron is bounded and transported in plasma by the non-heme and 1- globulin α transferring. During normal erythropoiesis, all of the circulating iron is bounded to α transferring and iron is turned over 6 to 10 times daily (Cavill, 1982), deposited wide variation in iron stores, the iron pool remain remarkable stable. Functional deficiency is defined by the delivery of less iron to the developing erythron than that required for optimal epoetin driven erythropoiesis (Besarab *et al.*, 1999). The provision of adequate iron to support the erythropoiesis in iron deficient patient is a time – consuming process. In a study aimed to evaluate the safety and tolerability of intravenous high dose iron sucrose therapy in-patient with iron deficiency anemia due to gastrointestinal blood loss Schroder *et al.*, (2004) concluded that this dose appears to be safe and therefore is a therapeutic option which may save time and improve patient compliance. Also in a patient with chronic kidney disease and severely anemic and iron deficient, an aggressive regimen of multiple high dose iron sucrose infusions may be both safe and effective (Schwenk and Blaustein , 2004).

Many studies indicated that adequate iron stores are critically necessary to achieve optimal responses to epoetin. If iron is released from its ferritin core, it may catalyze a variety of deleterious reactions (Besarab *et al.*, 1999) the result is the highly reactive hydroxyl radicals. A variety of methods are available for diagnosing iron overload, of these, assessment of hepatic iron index in a liver biopsy specimen (Bassett *et al.*, 1986) .

Efforts regarding dietary iron supply focused mostly on the prevention of iron deficiency anemia. The aim of this study is to evaluate iron supplementation as a quick aid to overcome certain types of anemia developed due to the severe shortage of food. In the meantime study of the effect of the short-term administration of iron on starved and well feed groups of animals by using routine histological examination.

MATERIALS and METHODS

Premature rabbits (*Oryctolagus cuniculus*) weighing about 0.750 kg were obtained from local market, Saudi Arabia. Twenty-four animals were housed in stainless steel cages under standard laboratory condition (14 hr light: 10 hr darkness) at $25 \pm 3^\circ\text{C}$ with constant humidity 40-60%. They were fed commercial diets, vegetables, crushed wheat and corn as a complete diet. They left for a week to be acclimatized. Then they were divided into 3 groups (8 each): one control group and two experimental groups, one well fed and the other starved as fed small amount of crushed wheat and corn (low iron diet) ones every morning and the rest of food removed quickly for two weeks, these two experimental groups (8 each) were supplemented daily by iron in a dose equivalent to the human therapies for three weeks later.

Therapeutic dose of human (33 mg/ kg / twice/ day), according to Paget and Barnes formula (1964) the equivalent dose of Fumarate was calculated (0.7 mg / rabbit/day). Fumarate tablets were crushed and dissolved in distilled water to form a suspension, suspension were force - fed by stomach tube to the experimental groups, daily till three weeks. After each week one control animal and 2 experimental ones were sacrificed. An out took of the organs, samples of livers and kidneys were put in 10% neutral formalin for fixation, embedded in paraffin wax, sectioned, stained by hematoxylin and eosin stains, diagnosed and photographed.

RESULTS

In the control group, animals were normally active and their size increase with the normal ratio with time .From the outlook; the mentioned organs were red in color.

The control group exhibited the general structure of liver as hepatocytes arranged in the form of branching and anatomizing plates forming lobules surrounding the central vein and separated by blood sinusoid (Figure 1).

Histological examination of control kidney revealed that it was distinguishable into an outer cortical region and an inner modularly region. The parenchyma of the cortex is formed of large number of renal tubules and Malpighian corpuscle consists of Bowman's capsule surrounding the glomeruli and the urinary space is found in between the two parietal layers (Figure 1*).

In starved group, animals were less active; their size decreased at the end of the second week about 30 %. Generally the organs were decolorized and became very pale at the end of the experiment. Histopathological examination of the rabbit liver revealed drastic alteration in his-architecture. The hepatocytes were disrupted; vacuolated with hyper chromic nuclei and lost their polyhedral shape. Vaculization was severe especially in the centrilobular region which showed widespread

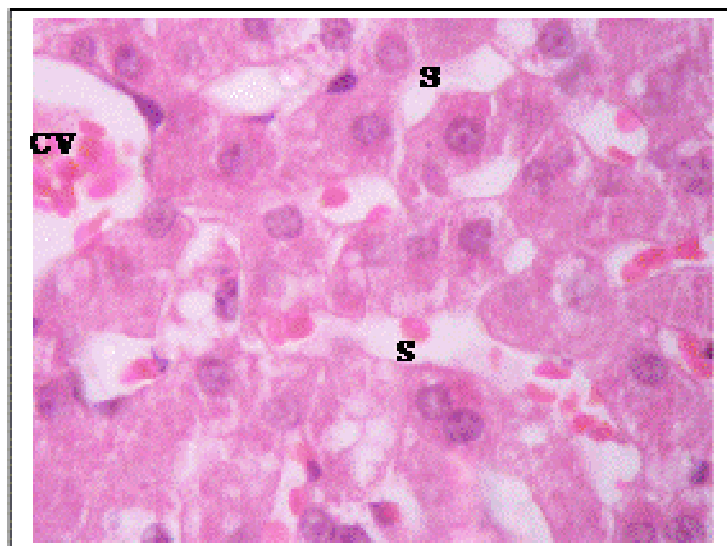


Figure 1. Control hepatic tissues showing hepatic strands of cells around the central vein (CV) leaving blood sinusoids (S) X750

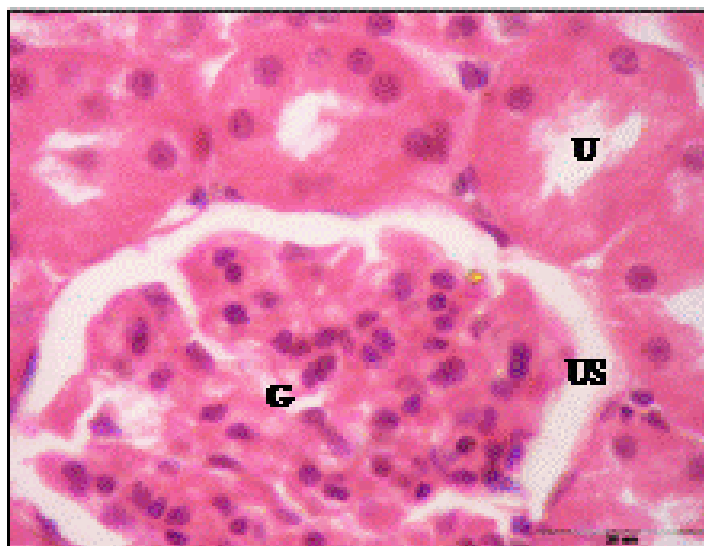

Figure 1*. Normal renal tissues showing normal uriniferous tubules (U) and glomeruli (G) with urinary space (US) X750.

necrosis; also cellular infiltration was detected around the blood vessels (Figure 2). In kidney, bale renal tissues are showing disrupted small uriniferous tubule and small Bowman's capsule with dilated urinary space (Figure 2*).

After one week of iron supplementation, the starved animals showed a moderate activity, their organs looked less pale, the liver and kidney showed moderate recovery from starving induced liver and kidney damage as well as recovery of some liver cells which appear with round nuclei and control amount of chromatin, no cellular infiltration, and certain iron deposition around the central

veins but still another disrupted cells show vacuolated cytoplasm and necrosis (Figure 3). Also the kidney showed improvement in all microscopic examination but some glomerular tufts were seen with vacuolation of mesangial cells accompanied with moderate vacular degenerative changes in few renal tubules as the cytoplasm of the tubular cells contained large vacuoles and the nuclei with condensed abnormal shape (Figure3*)

After three weeks of iron supplementation, the animal's activity was nearly normal and their internal organs looked pale red, and by time, the sections

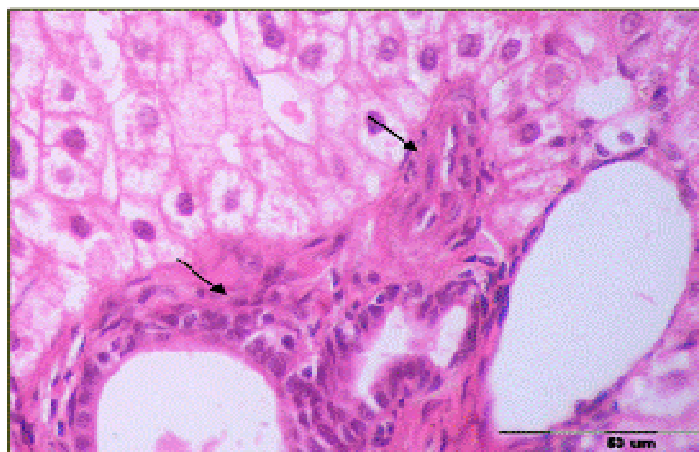

Figure 2. Starved hepatic tissues showing no sinusoids with cellular infiltration (→) around the portal vessels. X 750.

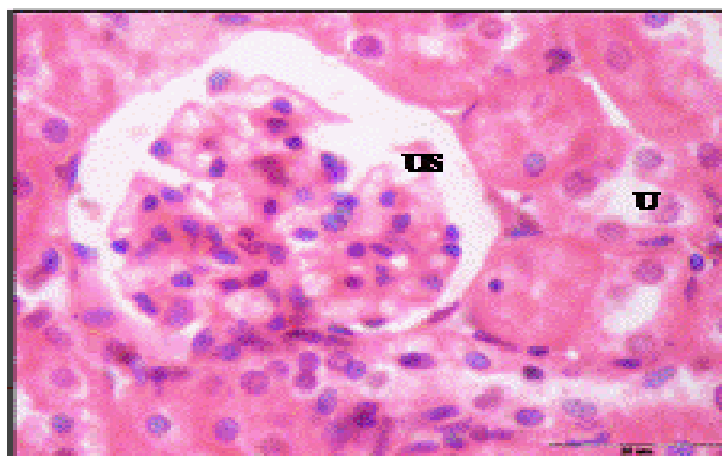

Figure. 2*. Pal renal tissues showing disrupted small uriniferous tubule (U) and dilated urinary space (US) X750.

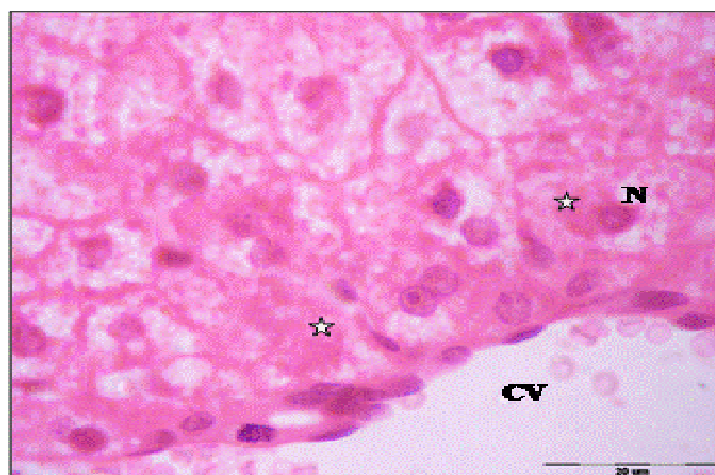

Figure 3. hepatic tissues after one week of iron supplementation showing iron accumulation in cytoplasm (☆) and nuclei (N) of hepatic cells around central blood vein (CV) X 750

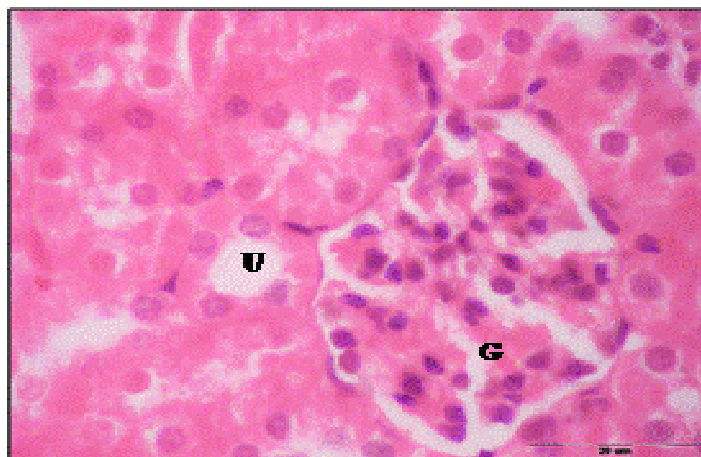

Figure 3*. Renal tissues after one week of iron supplementation showing small uriniferous tubule (U) and small glomeruli (G) X750.

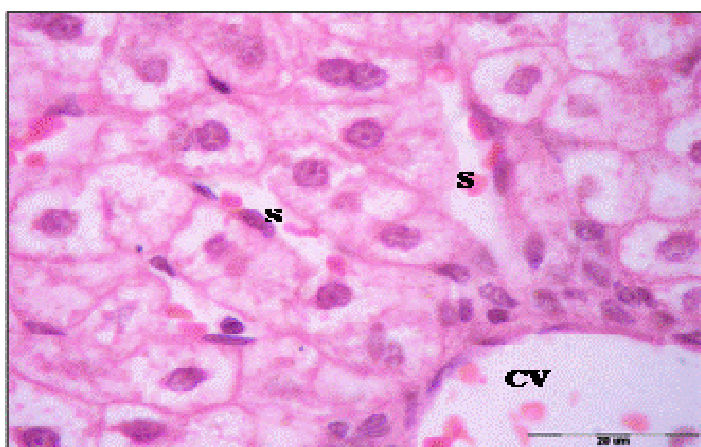



Figure 4. hepatic tissues after three weeks of iron supplementation showing nearly normal hepatic strands of cells around the central vein (CV) leaving blood sinusoids (S) X 750.

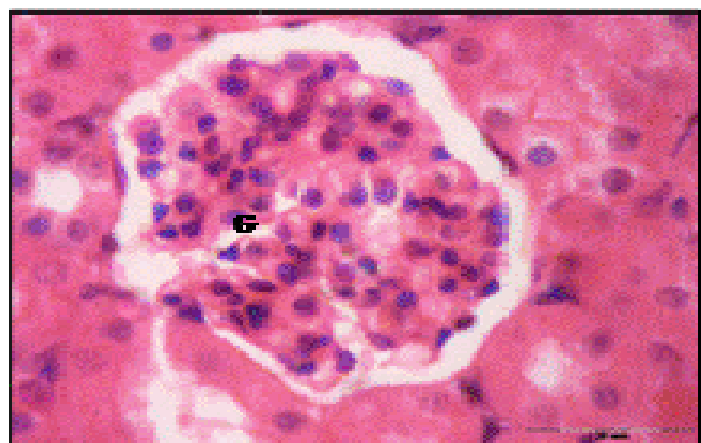

Figure 4*. Renal tissues after three week of iron supplementation showing iron accumulation in cytoplasm and nearly normal glomeruli (G) X750.

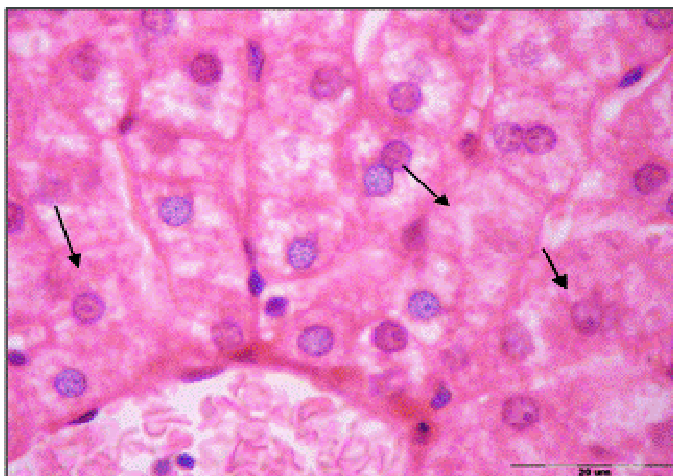

Figure 5. after one week of well fed with iron supplementation hepatic cells containing stainable granules scattered within the cytoplasm of the hepatic cells () X 750.

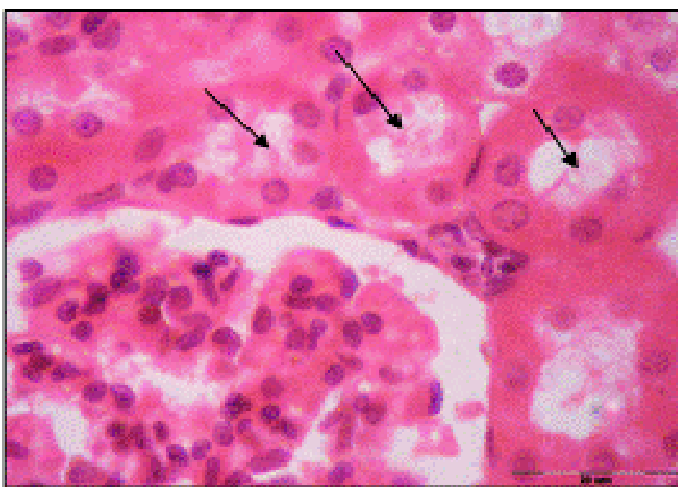




Figure 5*. after one week of well fed with iron supplementation the renal lumina were occupied by cellular casts () and hyaline material with disrupted brush border  X 750.

looked to be restoring the normal appearance, the deposition of iron or accumulation, was increased by time in dose-dependent manner as shown in the liver which showed well defined hepatic cords with polyhedral hepatocytes and normal appearing round nuclei (Figure 4) and in kidney the accumulation expanded to the whole section (Figure 4*).

In the well fed group, normal higher animal activity and more body size gains were observed, and the organs seemed to be normal in shape and red colour. The sections of liver and kidney showed certain iron accumulation, which looked dark, stained. After one week the nuclei of the liver cells were densely stained and the cytoplasm showed iron deposition, the cells arranged

regularly in lobules and central vein was congested, with shrinkage of blood sinusoids (Figure 5). Also kidney was completely blocked by dark stained iron deposition which in the form of granules scattered in the cytoplasm, and increased in volume and number by time and the lumina of many renal tubules were occupied by cellular casts and hyaline material with disrupted brush border (Figure 5*).

This accumulation exceeded a high rate by time and at the end of the third week causing Kupffer cell proliferation and some hepatic cells with ruptured cell membrane were observed (Figure 6), and renal tubules appeared irregular, dilated with flattened epithelial lining, and shrinkage of the glomerulus which led to

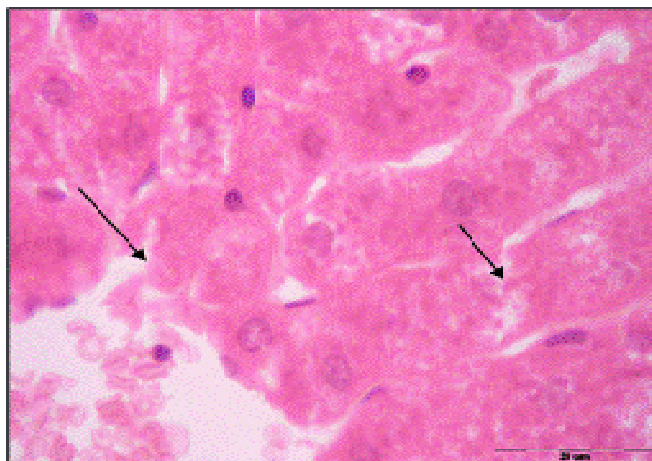

Figure 6. after three weeks of well fed with iron supplementation hepatic cells containing more stainable granules scattered within the cytoplasm of the ruptured hepatic cells (X 750.

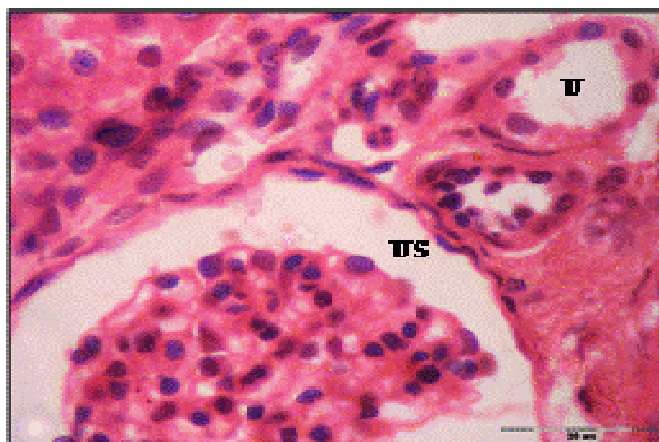

Figure 6*. After three weeks of well fed with iron supplementation .Dilated renal tubules with flattened epithelial lining (U) and dilated urinary space (US) X 750.

dilated urinary space (Figure 6*).

DISCUSSION

Iron supplementation, as known before, requires a highly complex set of regulatory approaches to meet demands of cells. In our experiment, iron is supplemented daily to the starved animals. This supplementation restored the moderate activity of these animals and their organs, which has been affected due to the shortage of food, and these animals and organs also appeared to be normal in colour and shape. In the meantime, the sections also restore the normal appearance. However, certain accumulation of stainable fine granules takes place. In this respect, it was concluded that both daily and weekly

iron supplementation reduced the prevalence of iron deficiency and anemia (De Marshi *et al.*, 1997). The daily supplementation was found to be more effective than weekly ones for increasing hemoglobin and ferritin and caused greater reduction of the risk of anemia (Auerbach *et al.*, 1998). The authors' depicted that the magnitude of hemoglobin response iron dependent on the amount of iron consumed. Current evidences suggested that supplementation should be taken daily to treat anemia, because the daily doses improved iron status. Whereas weekly ones was an effective way to prevent iron deficiency. Also, they reduced the side effects of excess iron accumulation (Schaefer and Schaefer, 1992 and MacDougall *et al.*, 1996) and oxidative stress (Navarro *et al.*, 1996) and maintained iron store for A long period when supplementation was stopped

(MacDougall *et al.*, 1996).

Homeostatic mechanisms increase intestinal iron absorption in iron deficiency, but its down regulation at high intake levels seems insufficient to prevent accumulation of high iron store at high intake. There is no regulation of iron excretion in overload. Excess of pharmaceutical iron may cause toxicity and therapeutic doses may cause gastrointestinal side effect. Chronic iron excess may lead to hepatic fibrosis due to iron amplification of oxidative stress and increases of DNA damages (Schumann, 2001).

The accumulation of iron in the starved animal liver observed here, may cause cytotoxicity due to the delivery of free radical or may be reflected after stopping supplementation, and the cells release an excess by certain ways. Besarab *et al.*, (1999) demonstrated that, to counteract the free radical and / or excess iron the cells use a primary line of defense involving superoxide dismutase, catalase, glutathione peroxidase. Phospholipids hydroxide glutathione peroxide provides a secondary line of defense, limiting membrane lipoperoxidation. Antioxidant such as vitamin E and C may limit the chain reaction formation of free radicals.

In contrast Viteri *et al.*, (1999) depicted in his review article that the significant differences in the distribution of hemoglobin and plasma ferritin argue in favor of long-term weekly supplementation rather than repeated short-term daily supplementation periods for improving iron reserves and controlling mild moderate anemia.

The excess accumulation of iron in the well-fed animal liver in this study was dose-time dependent. Iron accumulation was observed in those who have no iron deficiency and take drugs containing iron without any physician advice. This accumulation was found by Appel *et al.* (2001) who concluded that under administration of daily diet containing sufficient iron in different forms, iron was accumulated from the diet in liver, spleen and kidney in dose – dependent forms. Iron in its free ferrous and ferric forms may serve as a physiological regulator of normal intracellular functions but can be linked to several pathways of cellular toxicity (Tavill and Qadri, 2004), in particular oxidative stress induced cytotoxicity leading to necrosis which may be promoted by increased intracellular free iron (Mohamed *et al.*, 2006). Excess iron accumulation in the liver induces liver damage and promoting sub cellular organelles damage leading to cell death. Patients with iron overload frequently suffer from hemochromatosis of major organs, such as the heart and liver (Emara, *et al.*, 2006).

The accumulation which was shown here in the liver may be due to the link of excess iron with certain types of protein, transferrin, ferritin, heme - iron and non - heme free iron molecules. Knutson *et al.*, (2000) found that the daily supplemented iron to normal and deficient rats had liver non - heme iron concentration that were 1.8 - 2.7 fold higher respectively than those of the un supplemented normal rats .

The accumulated iron reported here was found to be very fine granules which enlarged by time. This observation agrees with certain evidence of (Cazzola *et al.*, 2003) who suggested that most of the iron deposited in the cells is in the form of mitochondrial ferritin. Magens *et al.*, (2005) demonstrated that the nuclear deposits of stainable iron in hepatocytes are a sign of liver iron overload in mice. The nuclear iron deposits were most abundant in all mice fed carbonyl iron (2.5 % w/w) for 52 weeks, almost irrespective of their genetic back ground. Under the electron microscope the nuclear iron deposition corresponded to aggregated ferretin molecules, represent a non - immunoreactive form of presumably denaturated ferritin.

REFERENCES

- Allen LH (2001). Biological mechanisms that might underlie iron's effects on fetal growth and preterm birth J. Nutr., 131: 581 - 589.
- Allen LH (2002). Iron supplements: Scientific issues concerning efficacy and implications for research and programs. J. Nutr., 132: 813 - 819.
- Allen, MJ Kuper CF, Woutersen RA (2001). Disposition, accumulation and toxicity of iron fed as iron (II) sulfate or as sodium iron EDTA in rats. Food Chem. Toxicol., 39 (3): 261 - 269.
- Auerbach M, Winchester J, Wahab A (1998). A randomized- trial of three iron dextran infusion methods for anemia in EPO - treated dialysis patients. Am. J. Kidney Dis., 31: 81 - 86.
- Bassett ML, Halliday JW, Powell LW (1986). Value of hepatic iron measurements in early hemochromatosis and determination of critical iron level associated with fibrosis. Hematology, 6: 24 - 26.
- Beard JL (2001). Iron biology in immune function muscle metabolism and neuronal functioning. J. Nutr., 131: 568- 579.
- Besarab A, Frinak S, Yee J (1999). Reviews: An Indistinct Balance, The safety and efficacy of parenteral iron therapy. J. Am. Soc. Nephrol., 10: 2029 - 2043.
- Cavill I (1982). Disorder of iron metabolism: Diagnostic methods. Clin. Hematol, 11: 259 - 273.
- Cazzola M, Invernizzi R, Bergamashi G, Levi S, Corsi B, Travaglio E, Rolandi V, Biasotto G, Drysdale J, Arosino P (2003). Mitochondrial ferritin expression in erythroid cells from patients with sideroblastic anemia. Blood, 101 (5): 1996 - 2000.
- De Marchi S, Cecchin E, Falletti E, Giacomello R, Stel G, Sepiacci G, Bortolotti N, Zanello F, Gonano F, Bartoli E (1997). Long - term effects of erythropoietin therapy on fistula stenosis and plasma concentrations of PDGF and MCP- 1 in hemodialysis patients. J. Am. Soc. Nephrol., 18: 1147 - 1156.
- Emara AM, Kelany RS, Moustafa KA (2006). Comparative Study of Protective Effect between Deferoxamine and Deferiprone on Chronic Iron Overload Induced Cardiotoxicity in Rats. The 30 Conference of the Egyptian Society of Histology and Cytology.
- Hallberg L, Hulthen L, Bengtsson C, Lapidul L, Lindstedt G (1995). Iron absorption from whole diet in men: how effective is the regulation of iron absorption? Am. J. Clin. Nutr., 66: 347 - 356.
- Knutson MD, Walter PB, Ames BN, Viteri FE (2000). Article: Both iron Deficiency and Daily iron supplements increase lipid. J. Nutr., 130: 621 - 628.
- MacDougall IC, Tucker B, Thompson J, Tomson CR, Baker LR, Raine AE (1996). A randomized controlled study of iron supplementation in patients treated with erythropoietin. Kidney Int., 50: 1694 - 1699.
- Magens B, Dullmann J, Schumann K, Wulfheke U, Nielsen P (2005). Nuclear iron deposits in hepatocytes of iron - loaded HFE knock - out mice: a morphometric and immunocyto chemical analysis. Acta Histochem., 107 (1): 57 - 65 .
- Mohamed FH, Amal MM, Amany SE, Azza RE, Nasra NA (2006). Effect of Chronic Overload on the Liver, Kidney and Pancreas of Albino Rat and the Possible protective Role of Vitamin-E, An

- Ultrastructural Study . The 30 Conference of the Egyptian Society of Histology and Cytology.
- Navarro JE, Teruel JL, Liano F, Marcen R, Ortuno J (1996). Effectiveness of intravenous administration of Fe- gluconate - Na complex to maintain adequate body iron stores in hemodialysis patients. *Am. J. Nephrol.*, 16: 268 - 272.
- Ponka P, Beaumont C, Richardson DR (1998). Function and regulation of transferrin and ferritin. *Semin. Hematol*, 35: 35 - 54.
- Prusak M, Grzegorzewska AE (2002). Causes of disturbances in iron turnover in chronic renal failure. *Pol. Merkuriusz Iok*, 12 (70): 309 - 313.
- Schaefer R, Schaefer L (1992). Management of iron substitution during hu EPO therapy in chronic renal failure patients. *Erythropoiesis*, 3: 71 - 75.
- Schroder O, Schrott M, Blumenstein I, Jahnel H, Dignass AV, Stein J (2004). A study for evaluation of safety and tolerability of intravenous high - dose iron sucrose in patient with iron deficiency anemia due to gastrointestinal bleeding .*Z. Gastroenterol.*, 42 (8): 663 - 667.
- Schumann K (2001). Safety aspects of iron in food. *Ann. Nutv. Metab*, 45: 91 - 101.
- Schwenk MH, Blaustein DA (2004). Rapid high-dose intravenous iron sucrose therapy in 2 Jehovah's Witness patients with severe anemia iron deficiency and chronic kidney disease. *Clin. Nephrol*, - 62 (2): 116 - 120.
- Tavill AS, Qadri AM (2004). Alcohol and iron. *Semin. Liver Dis.*, 24 (3) : 317 - 325 .
- Viteri FE, Ali F, Tujague J (1999). Article: Long - term weekly iron supplementation improves and sustains non - pregnant women's iron status a well or better than recommended short term daily supplementations. *J. Nutrit.*, 129: 2013 - 2020.
- WHO (1992). The prevalence of anemia in women: a tabulation of available information. WHO. Maternal Health and Safe Motherhood Programme, Nutrition Programme. Geneva, Switzer land PP 100.
- WHO (1999). UNICEF / UNU (United Nations University). Consultation on the control of iron deficiency. WHO. Geneva, Switzer.