

## Full Length Research Paper

# Antioxidant role of folic acid against reproductive toxicity of cyhalothrin in male mice

Hussein H.K<sup>\*1,2</sup>, Elnaggar M.H<sup>1,3</sup> and Al-Zahrani N.K<sup>1</sup>

<sup>1</sup>Department of Biological Sciences, Faculty of Science, King Abdulaziz University, Jeddah, Saudi Arabia

<sup>2</sup>Department of Zoology, Faculty of Science, Alexandria University, Alexandria, Egypt

<sup>3</sup>Department of Zoology, Faculty of Science, Suez Canal University, Ismailia, Egypt.

Accepted 15<sup>th</sup> May, 2012

The acute toxicity (LD50) of insecticide Cyhalothrin and its effects on male reproduction in rats were carried out. Cyhalothrin was given orally to male rats daily for 30 successive days at two doses (0.1 and 1.0 mg kg<sup>-1</sup> b.wt., corresponding to 1/100 and 1/10 LD50) alone and in combination with folic acid (1.1 mg kg<sup>-1</sup> b.wt., corresponding to acceptable daily intake, ADI). Fertility index, weight of sexual organs, and histopathology of testes were the parameters used to evaluate the reproductive efficiency of treated rats. The reversibility of Cyhalothrin effects was also studied after 30 days post-administration. The oral LD50 of Cyhalothrin was 20.0 mg kg<sup>-1</sup> b.wt. in male rats. Cyhalothrin significantly decreased the fertility index and weight of testes. It induced testicular lesions characterized by moderate to severe degenerative changes of seminiferous tubules and incomplete arrest of spermatogenesis. These toxic effects were not persistent (reversible). Co-administration of folic acid with Cyhalothrin decreased its reproductive toxicity. A great attention should be taken during field application of Cyhalothrin to avoid its deleterious effects in farm animals and occupationally exposed humans.

**Keywords:** Antioxidants, Cyhalothrin, Reproductive efficiency, Folic acid, Mice

## INTRODUCTION

Pesticides have brought about the green revolution in the world and are being widely used to control agricultural pests and insects causing public health hazards. Problems and/or outbreaks are reported to occur among animals and human from insecticide toxicity, which usually occurs either from direct exposure to insecticides or indirectly from contaminated feeds or water by such chemicals. Prolonged exposure to insecticides causes chronic neurological syndrome, malignant tumors, immunosuppressive action, teratogenic effect, abortion and decreased male fertility in experimental animals (Nafstad et al., 1983; El-Rahman, 1988; Al-Qwari et al.,

1999; Meeker et al., 2006; Youssef, 2010). Carbamates, derivatives of carbamic acid, represent a large variety of compounds which have some field applications as insecticides, herbicides and fungicides. Many of these chemicals are potential neurotoxicants, particularly following occupational, accidental or intentional exposure. These compounds cause reversible carbamoylation of the acetylcholinesterase enzyme, allowing accumulation of acetylcholine, the neuromediator at parasympathetic neuro-effector junctions (muscarinic effect) and autonomic ganglia (nicotinic effect) and in the brain or CNS effect (Oliveira-Silva et al., 2001).

Cyhalothrin acts as an insecticide against lepidopterous, suppresses coleopterous and some hemipterous insects. It acts as an ovicide against cotton bollworms and tobacco budworms (Mahgoub and Mednay, 2001). In Saudi Arabia, the use of insecticides

\*Corresponding Author E-mail: [ahssan555@yahoo.com](mailto:ahssan555@yahoo.com)

represents a great risk because of the huge amounts of insecticides used in the field and the lack of proper protective measures against pollution by these chemicals (El-Rahman, 1988).

Folic acid is necessary for the production of red blood cells and DNA synthesis. Folate is necessary for normal fertility in men and women as it is important during cell division and growth periods such as infancy and pregnancy. In males, foliate is necessary for spermatogenesis (Kamen, 1997).

The present work aimed to determine the acute oral LD50 of Cyhalothrin insecticide and to examine its toxic effects, alone and in combination with folic acid, on male fertility in rats.

## MATERIAL AND METHODS

### Insecticide

Cyhalothrin is a pyrethroid insecticide, an ingredient in the Karate brand of pesticides sold by Syngenta. Cyhalothrin is a fluorinated pyrethrin analog. Lambda-cyhalothrin is a mixture of highly active isomers of cyhalothrin. It was obtained from the stores of Agricultural Pesticides, Jeddah, Saudi Arabia in the form of a pure white crystal powder.

### Folic acid

Folic acid (Pteroylglutamic acid, Vit. B-9 or Vit. M) is a water soluble vitamin B member. It was obtained in the form of sodium foliate solution; equivalent of folic acid 5 mg/ml, from El Nahdi Company, Jeddah, Saudi Arabia.

### Animals

Male Swiss albino mice (MF1 strain), weighing  $31 \pm 2$  g and 8–10 weeks of age, were selected from inbred colony maintained in the Animal House of King Fahd center of medical research. The animals were kept under controlled hygienic conditions and maintained at a temperature of  $25 \pm 2$  °C, relative humidity of  $50 \pm 5\%$  and photoperiod at 12-h dark/ light. Rats were fed on rat pellets which composed of wheat bran 10%, soy bean powder 44%, net protein 22%, fats 4.7%, fibers 3.3%, fish meal, and molasses, salts (sodium chloride, calcium carbonate, and calcium phosphate). The diet was offered and water was allowed ad libitum during the experiment period. Mice were allowed to acclimatize to the laboratory environment for 7 days before start of the experiment.

### Acute toxicity experiment

For estimating the LD50 of cyhalothrin, 50 male Swiss albino mice were distributed into five groups each containing 10 animals. Mice were given orally, by stomach tube, the tested insecticide in graded doses. Toxic symptoms and the number of rats that died in each group after 48 h observation were recorded. The LD50 of cyhalothrin was then calculated according to the method described in Gad and Weil (1982).

### Fertility index

Effects of cyhalothrin at two dose levels (1/10 and 1/100 of the LD50) and folic acid at acceptable daily intake (1 mg kg<sup>-1</sup> b.wt.). For estimating the effect of cyhalothrin, folic acid and their combination on male fertility, 60 mature male mice were allocated into six equal groups. The 1<sup>st</sup> group (Control) was given orally 1.0 ml distilled water/day (vehicle) and kept as normal control. The 2<sup>nd</sup> and 3<sup>rd</sup> groups (A and B Groups) were given orally 1/100 (0.1 mg kg<sup>-1</sup> b.wt.) and 1/10 (1.0 mg kg<sup>-1</sup> b.wt.) of the LD50 of cyhalothrin, respectively. The 4<sup>th</sup> group (Group C) of male mice was orally given 20.0 mg kg<sup>-1</sup> b.wt. of folic acid calculated from acceptable daily intake (ADI) in man according to Paget and Barnes (1964) and 1/100 of the LD50 of cyhalothrin. The 5<sup>th</sup> (group D) was given 20.0 mg kg<sup>-1</sup> b.wt. of folic acid and 1/10 of the LD50 of cyhalothrin. The 6<sup>th</sup> one (group E), rats was only orally given 20.0 mg kg<sup>-1</sup> b.wt. of folic acid in the two last groups. Oral administration of the tested compounds continued for 30 consecutive days to cover the spermatogenic states according to Amann (1982). At the end of experiment, the mice were sacrificed and the left testis was removed and weighed. The testes were preserved in 10% neutral formalin solution till processed for histopathological examination (Bearden and Fluquary, 1980; Wilke and Utley, 1987).

### Histopathological examination

Testes of the treated mice were taken and fixed in 10% neutral formalin solution. The fixed specimens were then trimmed, washed and dehydrated in ascending grades of alcohol. These specimens were cleared in xylene, embedded in paraffin, sectioned at 4–6  $\mu$ m thickness and stained with Hematoxylen and Eosin (H and E) then examined microscopically according to Luna (1968).

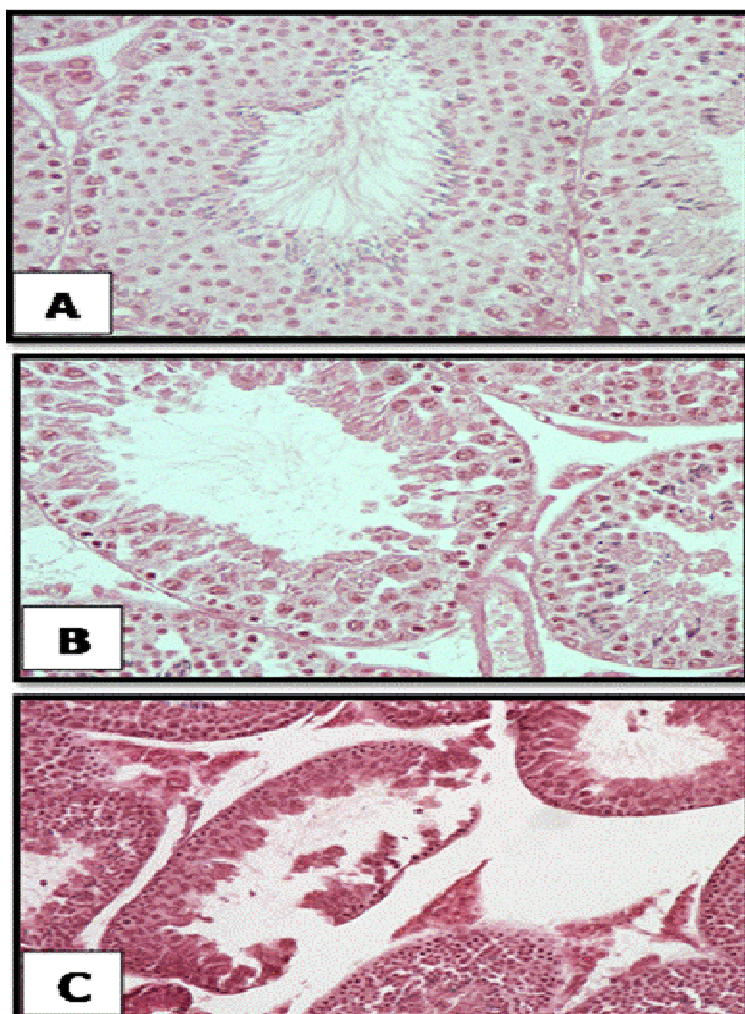
### Statistical analysis

All data were expressed as mean  $\pm$  S.E. and statistical analysis was carried using Student's 't' test according to Snedecor and Cochran (1986).

**Table 1.** Effect of cyhalothrin, folic acid and their combination on testicular measurements of male Swiss albino mice.

Parameters	Control	Group A	Group B	Group C	Group D	Group E
Germinal cell count	9.84 ± 0.64	9.11 ± 0.87*	7.34 ± 0.86**	8.08 ± 0.62*	7.96 ± 0.44	9.97 ± 0.21*
Lydig cell count	10.97 ± 1.25	10.21 ± 0.82*	8.52 ± 0.92**	9.40 ± 0.66*	8.85 ± 0.34*	10.12 ± 1.25
Primary and secondary Spermatoocytes count	46.11 ± 2.58	44.78 ± 2.90*	41.39 ± 2.74**	45.18 ± 2.55*	44.11 ± 2.74**	47.09 ± 2.32*
Seminiferous tubule diameters (µm)	4.85 ± 0.36	4.14 ± 0.47**	3.98 ± 0.33**	4.11 ± 0.48**	4.02 ± 0.41*	4.33 ± 0.18

Results are presented as Mean ± SD \*p<0.001; \*\*p<0.01; \*\*\*p<0.001



**Figure 1.** Testicular structure of the (A) control Rats showing normal and regular seminiferous tubules, (B) Cyhalothrin-treated group B (0.1 mg/kg) showing the pathologic effects in which the structures of the seminiferous tubules were severely damaged and (C) Cyhalothrin -treated group (1.0 mg/kg) in which the thickness of the tubular walls was reduced. The number of germinal cells was greatly decreased with a disturbance in their diameter. X400 (H and E Stain).

## RESULTS

Group A showed a significant decrease in the numbers of germinal ( $p < 0.001$ ), Leydig ( $p < 0.001$ ) and spermatocyte (primary and secondary) cells ( $p < 0.01$ ) when compared to the controls. These differences were highly significant between controls and group B, however, the numbers of spermatocytes in group B were significantly lower than in the control group (Table 1;  $p < 0.01$ ). The numbers of germinal cells, Leydig cells and spermatocytes in group A were significantly lower than those in control [(9.11 vs. 9.84;  $p < 0.001$ ); (10.21 vs. 10.97;  $p < 0.001$ ); (44.78 vs. 46.11;  $p < 0.01$ )].

The diameters of seminiferous tubules were smaller in groups A and B, but a significant difference was seen only in group A compared to the control group ( $p < 0.01$ , Table 1). In C and D groups in which the mice were given cyhalothrin and after 2–4 h mice were given ADI of folic acid, all measurements were significantly lower than in the control group. Generally The numbers of germinal cells, Leydig cells, spermatocytes and seminiferous tubules were significantly lower in group D were significantly lower than those in group C ( $p < 0.01$ , Table 1). In last group (group E), in which rats was only orally given 20.0 mg kg<sup>-1</sup> b.wt. of folic acid, there was no significant difference between this group and control one (Table 1).

The structures of the seminiferous tubules in cyhalothrin-treatment groups were pathologically damaged (Figures. 1B, C) in comparison to the control group (Figure. 1A). Testicular structure of the control group showing normal and regular seminiferous tubules. Cyhalothrin-treated group B (0.1 mg/kg) showing the pathologic effects in which the structures of the seminiferous tubules were severely damaged and Cyhalothrin -treated group (1.0 mg/kg) in which the thickness of the tubular walls was reduced. The number of germinal cells was greatly decreased with a disturbance in their diameter (Figures. 1 A, B and C).

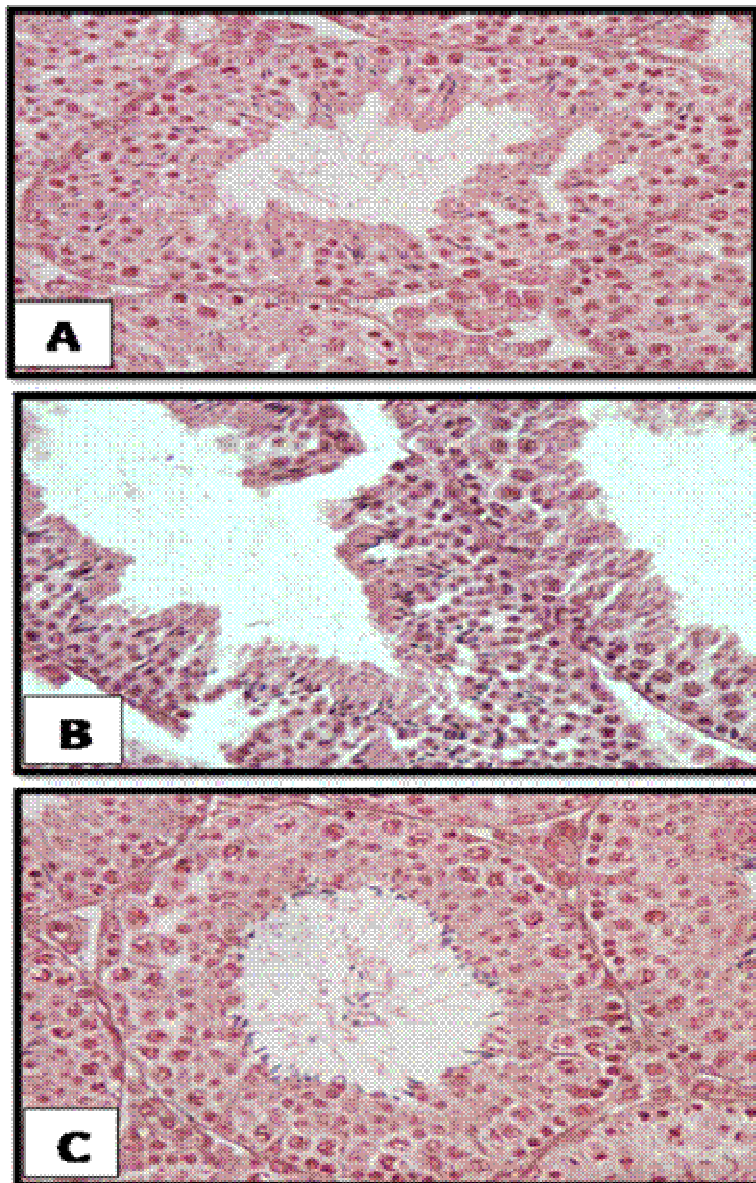
The seminiferous tubules structure in cyhalothrin-treatment groups combined with folic acid was illustrated in (Figure 2). Testicular structure of the low dose cyhalothrin and folic acid rat group showing sustainable normal but irregular seminiferous tubules with large intercellular space (Figure 2A). High dose cyhalothrin and folic acid-treated group showing decrease pathologic effects in which the structures of the seminiferous tubules were slightly damaged with bleeding in intercellular space (Figure 2B). In folic acid -treated group, normal and regular seminiferous tubules were clearly appears. The germinal cells were greatly regulated with normal diameter and mild dilatation of the seminiferous tubules with normal complete spermatogenic series (Figure 2C).

## DISCUSSION

Reproductive abnormalities caused by Pyrethroid insecticides have been observed in many vertebrates, such as inhibition of spermatogenesis in fish and mice (Contreras and Bustos-Obregón, 1999; Sobarzo and Bustos-Obregón, 2000; Meijer, 2003). Alteration of germinal cell DNA, seminiferous epithelium and low quality of sperm have been reported previously (Oliveira-Silva et al., 2001; Swan, 2006; Recio-Vega, 2008). Alahyary et al. (2008) have shown that blood glucose and testosterone levels were increased in a Diazinon insecticide treated group compared with a control group, moreover the number of red blood cells (RBC) in the Diazinon group was significantly decreased in comparison with the controls. Dikshith et al (1975) observed mild structural and functional changes in rat testes after a single LD 50 IP dose administration of Diazinon. Dutta and Meijer (2003) investigated the toxic effects of organophosphorus insecticide on the structure of the testis of bluegill fish. They found a significant change in the germ cells and seminiferous tubule diameters (Dutta and Meijer, 2003). In the present study we found that cyhalothrin had a significant effect on the structure of rat testes.

There was a significant reduction in both seminiferous tubule size and germinal cell count in the cyhalothrin treated groups, especially group A. As germ cells are the essential first step in the process of spermatogenesis, a reduction in their count may hinder the production of viable spermatozoa (Dutta and Meijer, 2003). Contreras et al. (2006) have shown that the number of Leydig cells and steroidogenesis are acutely and deeply damaged by OP injection in mice. In our study the number of Leydig cells was significantly decreased by insecticide treatment. Testicular Leydig cells are the main site of testosterone synthesis (Contreras et al., 2006). This steroidal hormone plays a key role in the maintenance of spermatogenesis, male sex characteristics and fertility (Contreras et al., 2006). As a consequence of impaired Leydig cell activity, male infertility may result (Contreras et al., 2006).

Some studies have shown that a decreased testicular Leydig cell count is associated with decreased testosterone production, which may result in spermatogenic deficiencies (Dutta and Meijer, 2003; Maxwell and Dutta, 2005). All these studies are come in agreement with the present study, Cyhalothrin as a pyrethroid insecticide has toxic effects on male reproduction. In our study the toxic effect of Cyhalothrin on rat testes in group A was significantly higher than that in group B. These data suggest that the toxic effects of Cyhalothrin on rat testes are dose dependent. Although this reproductive dysfunction is typically characterized by disruptions in spermatogenesis and loss of fertility, the actual mechanisms involved in Cyhalothrin-induced infertility remain unclear. Kurodak et al. (1992) explained that Diazinon insecticide led to cell injury by mitotic



**Figure 2.** Testicular structure of the (A) Low dose cyhalothrin and folic acid rat group showing sustainable normal but irregular seminiferous tubules with large intercellular space, (B) High dose cyhalothrin and folic acid-treated group showing decrease pathologic effects in which the structures of the seminiferous tubules were slightly damaged with bleeding in intercellular space and (C) Folic acid -treated group (20 mg/kg) showing normal and regular seminiferous The germinal cells was greatly regulated with normal diameter and mild dilatation of the seminiferous tubules with normal complete spermatogenic series. X400 (H and E Stain).

toxicity, chromatin destruction and DNA disturbances. Some research has shown decreased testosterone production by Leydig cells in insecticide treated groups to be one of these mechanisms (Abdel-Aziz et al., 1994; Maxwell and Dutta, 2005; Contreras et al, 2006). The Leydig cells produce the testosterone needed in the seminiferous tubules to induce the differentiation of spermatogonia to spermatozoa (Contreras et al., 2006).

Because testicular Leydig cells play a critical role in male reproductive function, alterations in the Leydig cells could be due to many different pathological or experimental situations associated with spermatogenesis deficiency (Dufau, 1979; Walsh et al., 2000). Reactive oxygen species (ROS) caused by insecticide treatment may be involved in the toxicity of various pesticides (Walsh et al., 2000). Increased ROS may decrease the effective

concentration of antioxidant, increasing the harmful effects of ROS to reproductive tissue (Agarwal and Prabakaran, 2005). Sutcu et al. (2007) have shown that insecticide treatment caused an increase in lipid peroxidation (LPO) in rat erythrocytes. Because spermatozoa have large quantities of polyunsaturated fatty acids (PUFA) in their plasma membranes and their cytoplasm contains low concentrations of scavenging antioxidants (Agarwal and Prabakaran, 2005), a causal relationship is suspected. Thus, it is hypothesized that oxidative damage induced by Cyhalothrin insecticide may be one of these mechanisms which merit future study.

## REFERENCES

- Abdel-Aziz MI, Sahlab AM, Abdel-Khalik M (1994). Influence of diazinon and deltamethrin on reproductive organs and fertility of male rats. *Dtsch Tierarztl Wochenschr.* 101(6): 230-232.
- Agarwal A, Prabakaran SA (2005). Mechanism, measurement and prevention of oxidative stress in male reproductive physiology. *Indian J. Experim. Biol.* 43: 963-974.
- Alahyary P, Ilkhani Poor M, Fathy Azarbajani F, Nejati V (2008). The potential toxicity of diazinon on physiological factors in male rat. *Pak J. Biol. Sci.* 11:127-130.
- Al-Qwari A, Al-Damegh MS, Adam SE (1999). Effect of amitraz insecticides given by different routes on rats. *Veterinary and Human Toxicology* 41 (6), 355–357.
- Amann RP (1982). Use of animal models for detecting specific alteration in reproduction. *Fundamentals of Applied Toxicology* 2, 13–36.
- Bearden HJ, Fluquary J (1980). *Applied Animal Reproduction*. Reston Publishing Co. Inc., Reston, Virginia, USA. pp. 158–160.
- Contreras H, Bustos-Obregón E (1999). Morphological alterations in mouse testes by a single dose of Malathion. *J. Exp. Zool.* 284: 355-359.
- Contreras HR, Paredes V, Urquieta B, Del Valle L, Bustos-Obregón E. (2006). Testosterone production and spermatogenic damage induced by organophosphorus pesticides. *Biocell.* 30: 423-429.
- Dikshith TS, Behari JR, Datta KK, Mathur AK (1975). Effect of diazinon in male rats. *Histological and Biochemical studies. Environ. Physiol. Biochem.* 5:239-299.
- Dufau ML, Cigorruga S, Baukal AJ, Bator JM, Neubauer JF, Catt KJ (1979). Androgen biosynthesis in Leydig cells after testicular desensitization by LHRH and hCG. *Endocrin.* 105: 1314-1321.
- Dutta HM, Meijer HJ (2003). Sublethal effects of diazinon on the structure of the testis of bluegill, *Lepomis macrochirus*: a microscopic analysis. *Environ. Pollut.* 12: 355-360.
- El-Rahman HA (1988). Effect of Organophosphorus Compound, Phoxim (Vordon) on Reproduction in Rats. M.V.Sc. Thesis Presented to Pharmacology Department, Faculty of Veterinary Medicine, Cairo University.
- Gad CS, Weil SC (1982). In: Hays AW (Ed.), *Principles and Methods of Toxicology*, 2nd ed. Raven Press, USA, pp. 292–293.
- Kamen B (1997). A review on foliate and antifolate pharmacology. *Seminars in Oncology* 24 (5), 18–39.
- Kurodaka Yamaguchi, Endo G (1992). Mitotic toxicity sister chromatid exchange, andrec assay of pesticides. *Arch. Environ. Contam. Toxicol. Japan.* 23: 13-18.
- Mahgoub AA, Mednay AH (2001). Evaluation of chronic exposure of male rat reproductive system to insecticide methomyl. *Pharmacological Research* 44 (2), 73–80.
- Maxwell LB, Dutta HM. 2005; Diazinon-induced endocrine disruption in bluegill sunfish, *Lepomis macrochirus*. *Ecotoxicol Environ Saf.* 60: 21-27.
- Meeker JD, Ryan L, Barr DB, Hauser R (2006). Exposure to non persistent insecticides and male reproductive hormones. *Epidemiology* 17, 61–68.
- Nafstad I, Berge G, Sannes E, Lyngest A (1983). Teratogenic effect of organophosphorus, fenchlorphos, compound in rabbits. *Acta Veterinaria Scandinavica* 24 (3), 295–304.
- Oliveira-Silva JJ, Alves SR, Meyer A, Perez F, Sarcinelli PN, Da Costa Mattos RC. 2001; Influence of socioeconomic factors on the pesticides poisoning, Brazil. *Rev Saude Publica.* 35: 130-135.
- Recio-Vega R, Ocampo-Gomez G, Borja-Aburto VH, Moran-Martínez J, Cebrian-Garcia ME (2008). Organophosphorus pesticide exposure decreases sperm quality: association between sperm parameters and urinary pesticide levels. *J. Appl. Toxicol.* 28: 674-680.
- Sobarzo C, Bustos-Obregón E (2000). Sperm quality in mice acutely treated with parathion. *Asian. J. Androl.* 2: 147-150.
- Sutcu R, Altuntas I, Buyukvanli B, Akturk O, Ozturk O, Koylu H (2007). The effects of diazinon on lipid peroxidation and antioxidant enzymes in rat erythrocytes: role of vitamins E and C. *Toxicol. Indust. Health.* 23: 13-17
- Swan SH (2006). Semen quality in fertile US men in Relation to geographical area and pesticide exposure. *Int. J. Androl.* 29: 62-88.
- Walsh LP, McCormick C, Martin C, Stocco DM (2000). Roundup inhibits steroidogenesis by disrupting steroidogenic acute regulatory (StAR) protein expression. *Environ. Health Perspec.* 108: 769-776.
- Wilke TJ, Uitley DJ (1987). Total testosterone, free androgenic index and calculated free testosterone by analog RIA method. *Clinical Chemistry* 33, 1372–1375.
- Youssef MI (2010). Vitamin E modulates reproductive toxicity of pyrethroid lambda-cyhalothrin in male rabbits. *Food and Chemical Toxicology* 48 (5), 1152–1159.