



## Case Report

# Copper nanoparticles as treatment of diabetic foot ulcers: A case report

T. Lopez Goerne<sup>1,2\*</sup>, A. Arévalo<sup>3</sup>, P. Ramírez<sup>1</sup> and P. Larraza<sup>1</sup>.

<sup>1</sup>Laboratorio de Nanotecnología y Nanomedicina, Departamento de Atención a la Salud. Universidad Autónoma Metropolitana-Xochimilco. Calzada del Hueso 1100, Col. Villa Quietud, Delegación Coyoacán, C. P. 04960, Ciudad de México.

<sup>2</sup>Facultad de Medicina, Universidad Nacional Autónoma de México.

<sup>3</sup>Laboratorios de Nanomedicina y Nanotecnología. Nano Tutt S.A. de C.V.

Accepted 27 October, 2017

**Copper nanoparticles were prepared by the sol-gel process to obtain nanoparticles of 2.4 nm. The material was characterized by Transmission Electron Microscopy (TEM) and Fourier Transformed Infrared Spectroscopy (FTIR). This nanomaterial was used to treat a diabetic foot ulcer in a 58 years old male patient. The patient presented type 2 diabetes mellitus with 13 years of evolution, with macro and micro vascular complications. The illness shown by retinopathy, state 2 chronic renal disease, peripheral artery disease, critical limb ischemia with the presence of an ulcer in the right heel and an ipsilateral necrotic lesion in the 2nd, 3rd, and 4th toes. This patient was already programmed for a supracondylar amputation. In order to avoid the amputation, the patient was included into the clinic trial to be treated with copper nanoparticles. After a three-month treatment, the ulcer evolved with positive clinical results.**

**Keywords:** Nanoparticles, copper, diabetic foot, ulcers, diabetes, case report

## INTRODUCTION

The OMS defines diabetic foot as “the infection, ulceration and destruction of deep tissues in the inferior extremity, associated with neurological alterations and different degrees of the peripheral vascular illness”. It is defined as a multifactorial disease, its attention has to be integrated and given by an interdisciplinary team so that any complications can be detected on time, and to provide a well-structured treatment that allows a faster healing which improves the evolution and avoids the sequels of diabetes in the feet (Nacionales, 2012; Amin and Doupis, 2016; Volmer-Thole and Lobmann, 2016; Dahiru et al., 2016; Apelqvist, 2012; O’Loughlin et al., 2010).

Diabetic Foot Ulcers (DFU) are relatively frequent in Mexico, between 40% and 50% of the population with diabetes eventually develops DFU through their life and 20% of the cases undergoes as amputations (Ética, 2015; Surgeons, 2012; Guadarrama, 2011; Ruiz et al., 2013; Vásquez-garcía, 2015; Castro et al., 2009)

DFU have a first order economical effect. Of course, these numbers do not have in account the indirect cost for the patient as the effect on the social wealth effect, the psychological and physical and the fact that many patients will not be able to work during a long period of time due to their injuries (Kanchanasamut and Pensri, 2017; Practice, 2013). “The usual impression that there is nothing to do, that it is not worth it, that everything fails, and that the amputation is only postpone, doesn’t have any scientific base. The reality is that 90% of the cases

\*Corresponding Author E-mail: [tessy3@prodigy.net.mx](mailto:tessy3@prodigy.net.mx)

are revascularized with higher percentage of success of 85% in a year and more or less 50% in five years" (Limb et al., 2013; Alavi et al., 2014). Unfortunately the patients seek for medical attention at very advanced stages and many times do not count with the economic support to realize procedures as revascularization that is why it is important to have products that can offer an option of improvement for the patient (Tarride et al., 2010; Rao et al., 2017; Godoy-Santos et al., 2017; Günal et al., 2015; Akkurt et al., 2017).

Among the many chemical techniques for the fabrication of materials, sol-gel technology has emerged as an effective route to control the size, morphology, structure, and physical and chemical properties of inorganic oxides. The sol-gel synthesis based on the hydrolysis and subsequent condensation of metal alkoxide precursors provides several advantages such as a low temperature process to obtain materials with a high level of atomic mixing and a high degree of porosity and a wide variety of shapes (Smith and Gambhir, 2017).

The properties of titania-silica mixed oxides are strongly dependent on their chemical composition, homogeneity, and texture, which in turn depend on synthesis conditions. The incorporation of an active metal in the sol during the gelation stage allows the metal to have a direct interaction with the support (Hajimiri et al., 2016; Moura et al., 2013; Sandri et al., 2013). This active metal will be finally in the external surface, as well as in the internal surface, therefore the material is bonded to the support by Van der Waals forces and possess special catalytic properties (Haycocks et al., 2011).

Several studios have developed nanoparticulate materials at the nano scale and at the same time evaluate their biological and pharmacological effects as well as the medical applications (Kim et al., 2010; López and Rodríguez, 2015). In the present case, a new nanomaterial synthesized by the Sol-Gel technique was used for DFU treatment, a significant improvement was observed in the wound healing process, in spite of the poor health conditions of the patient. A detailed characterization was also performed for this material using FTIR and TEM (Piao et al., 2008; Dastjerdi and Montazer, 2010).

## METHODOLOGY

A flask with water and ethanol (Sigma Aldrich 99.8%) was kept at room temperature and constant stirring, the adequate amount of copper acetylacetonate (Aldrich 97%) was added to this mixture, then the pH of the mixture was adjusted to pH 1 with H<sub>2</sub>SO<sub>4</sub> and H<sub>3</sub>PO<sub>4</sub> (Aldrich 98%). During a period of 7 h, tetraethyl orthosilicate (Aldrich 98%) and titanium butoxide (Aldrich 97%) were added dropwise to the mixture under stirring. Once the alkoxides were completely added, the temperature was increased while stirring until gelation.

The Cu/TiO<sub>2</sub>-SiO<sub>2</sub> is obtained when the gel is dried. Then the nanoparticles were incorporated into a polymeric gel matrix. Procedure of secrecy No. 101/100/014/13.

**Protocol: "Seguridad y eficacia de la aplicación local de nanomateriales de Pt/SiO<sub>2</sub>-TiO<sub>2</sub> en pacientes con úlceras de pie diabético" Dirección de Educación e Investigación JUDI-01/ 07 CDMX.**

## Patient clinical history

A 58 year-old male patient from Mexico City presents a family history of diabetes and hypertension presents a family history of diabetes and hypertension from both mother and father lineage. Merchant, smoker (45 pack-year smoking history), refers cocaine and marijuana consumption during 4 years and chronic alcoholism suspended 6 years ago. Presents type 2 diabetes mellitus for 13 years treated with biguanide and insulin 30-0-20, with medication non-adherence problems. The patient refers previous hospitalization a month before the evaluation, as consequence of a hyperosmolar hyperglycemic state requiring intensive care management. He also has a depressive disorder background of four years of evolution treated with a selective serotonin reuptake inhibitor. Also presents diabetic retinopathy diagnosed two years ago without any treatment and stage 2 chronic kidney disease. The patient was discharged with an ulcer in the right heel and necrotic injuries in the 2<sup>nd</sup>, 3<sup>rd</sup> and 4<sup>th</sup> toes, 15 days after being discharged, he had an appointment in the external surgery service where he was programmed for supracondylar amputation, the patient refused the surgery and attended to be patient refused the surgery and attended to be evaluated to get the Cu/TiO<sub>2</sub>-SiO<sub>2</sub> nanoparticles treatment.

During physical exploration blood pressure was 140/90 mmHg, heart frequency had a rate of 88 beats per minute, respiratory rate of 20 breaths per minute, temperature was 36.5 °C. Partially hydrated with light pallor in the right leg tegument with edema up to the medium third of the tibia, with loss of movement down from the knee to the feet, with toe nails thickening, presented a heel ulcer of about 10.5 x 7 cm with gangrenous borders, the base of the injury has 70% of fluctuating and gangrenous tissue, the perilesional skin showed edema and erythema, the wound also had odorous suppuration. Second, third and fourth toes presented necrotic tissue. There were no pedal nor tibia pulses, the feet were cold with light dorsal cyanosis. The sensibility and reflexes at the foot were diminished. X-rays of the foot showed no evidence of bone affection.

The patient was also evaluated at the vascular and angiology surgery service with a report of critical ischemia being candidate for revascularization procedure on the right leg but due to the lack of economic resources, the patient did not have the procedure and decided to use.

## Clinical diagnosis

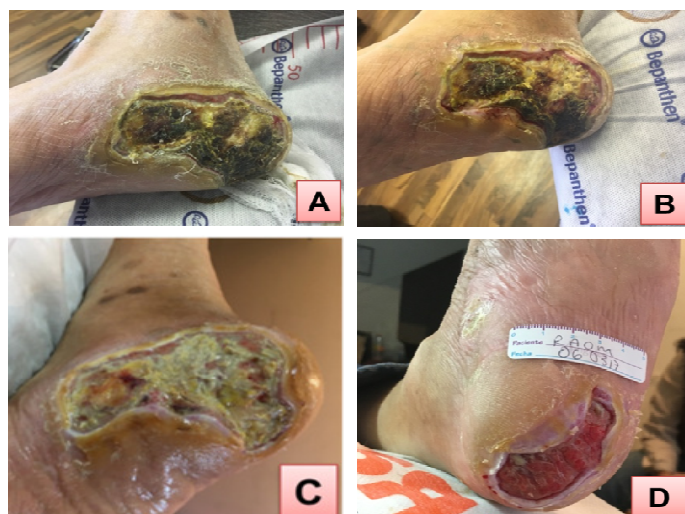
Diabetic right foot Texas IID degree with neuroischemia. Risk factors for ischemia: male, type 2 diabetes mellitus antecedents, smoking person, and chronic kidney disease.

## Treatment

Due to the patient's economical and clinical status it was decided to include him for treatment with Cu/TiO<sub>2</sub>-SiO<sub>2</sub>. This alternative becomes viable because the action mechanism allows to maintain the tissue dryness and at the same time inhibits bacterial proliferation by means of a bio catalytic effect.

In the first valuation antibiotic therapy was started for gram-positive and anaerobic bacteria as well as analgesic medication for pain management, an adjustment in the previous diabetes mellitus treatment was done because of the metabolic decontrol of the patient, we worked together with a nutritionist and a psychologist to treat the psychiatric disorder. As it is in the DFU manage guide we started with local application of iodopovidone. No debridement of the fluctuating necrotic tissue was performed because of the previous report of an arterial ulcer. After three weeks of treatment the heel injury no longer had necrotic tissue, it became dry and the size and depth were significantly reduced. After a month of Cu/TiO<sub>2</sub>-SiO<sub>2</sub> nanoparticles treatment the necrotic tissue of the 2<sup>nd</sup>, 3<sup>th</sup> and 4<sup>th</sup> toes disappeared presenting complete epithelialization below them.

After two months of treatment the injury in the base of the heel was completely clean and had a multiplying granulating tissue, although a delay in the cicatrization was observed so the nanogel was replace by an hydrocolloid apposite, nowadays the injure is completely repithelialized (Figure 1).



**Figure 1.** Evolution of the patient's wound after Cu/TiO<sub>2</sub>-SiO<sub>2</sub>treatment.

## DISCUSSION

The clinical case presented, had several risk factors that seriously complicate the wound healing, critical ischemia, the low patient attachment to the treatment, depression, nutritional and physiological status, nicotism, etc. Unfortunately, in México and many of the developing countries this cases are very common, the majority of the patients attend to a doctor in similar circumstances and because of this so deplorable state of health, the only choice for them is amputation, however, most of them refuse the amputation even though their life is at risk. A fast absorption and immediate action alternative treatment as Cu/TiO<sub>2</sub>-SiO<sub>2</sub> that helps to local holding of the infection in a subject with serious vascular problems gives to this kind of patients a new opportunity to improve their quality of life.

## CONCLUSIONS

In this case, we observed a favorable clinic evolution of the patient even though there was a severe previous complication in the blood contribution at the legs level. In this patient the use of Cu/TiO<sub>2</sub>-SiO<sub>2</sub>nanoparticles gel showed an evident improvement, so due to the patient's evolution, we can conclude that Cu/TiO<sub>2</sub>-SiO<sub>2</sub>can be used as a primary apposite to stimulate the autolytic debridement on injures, so we can confer it the next physical-pharmaceutical properties:

- Excellent local absorption and immediate effects because of its nanoparticulate composition.
- Humid environment maintenance, because the gel contains 85% of water allowing to keep the necrotic tissue hydrated hence enhancing its detachment.
- Due to the adsorbent properties of the silica there is a control of the injury suppuration.
- The bactericide action of the titanium oxide helps to control local infections.

It is important to emphasize that the success of this case was also due to the integral management of the treatment thanks to the collaboration of an interdisciplinary team.

## REFERENCES

- Akkurt MO, Demirkale I, Öznur A (2017). Partial calcaneotomy and Ilizarov external fixation may reduce amputation need in severe diabetic calcaneal ulcers. *Diabet Foot Ankle.* 8(1):1264699. doi:10.1080/2000625X.2017.1264699.
- Alavi A, Sibbald RG, Mayer D, et al (2014). Diabetic foot ulcers: Part II. Management. *J. Am. Acad. Dermatol.* 70(1):21.e1-21.e24. doi:10.1016/j.jaad.2013.07.048.
- Amin N, Doupis J (2016). Diabetic foot disease: From the evaluation of the "foot at risk" to the novel diabetic ulcer treatment modalities. *World J. Diabetes.* 7(7):153. doi:10.4239/wjd.v7.i7.153.
- Apelqvist J (2012). Diagnostics and treatment of the diabetic foot. *Endocrine.* 41(3):384-397. doi:10.1007/s12020-012-9619-x.

- Castro G, Liceaga G, Arrijoja A, et al (2009). Artículo de revisión Guía clínica basada en evidencia para el manejo del pie diabético. Artículo de revisión. 25(6):481-526.
- Dahiru I, Amaefule K, Okpe I, Ibrahim A, Muazu S (2016). An overview of diabetic foot disease. *Niger. J. Basic Clin. Sci.* 13(1):1. doi:10.4103/0331-8540.176206.
- Dastjerdi R, Montazer M (2010). A review on the application of inorganic nano-structured materials in the modification of textiles: Focus on anti-microbial properties. *Colloids Surfaces B Biointerfaces.* 79(1):5-18. doi:10.1016/j.colsurfb.2010.03.029.
- Ética Q De (2015). Ortopedia y Traumatología. *Rev. Colomb. Ortop. y Traumatol.* doi:10.1016/j.rccot.2015.04.006.
- Godoy-Santos AL, Amodio DT, Pires A, et al (2017). Diabetic limb salvage procedure with bone allograft and free flap transfer: a case report. *Diabet Foot Ankle.* 8(1):1270076. doi:10.1080/2000625X.2016.1270076.
- Guadarrama FC (2011). Cuidado de los pies en usuarios que viven con diabetes en el estado de México: bases para la sistematización de la asistencia de enfermería. 2(1):23-27.
- Günal Ö, Tuncel U, Turan A, Barut S, Kostakoglu N (2015). The Use of Vacuum-Assisted Closure and GranuFoam Silver ® Dressing in the Management of Diabetic Foot Ulcer. *Surg Infect (Larchmt).* 16(5):558-565. doi:10.1089/sur.2014.093.
- Hajimiri M, Shahverdi S, Esfandiari MA, et al (2016). Preparation of hydrogel embedded polymer-growth factor conjugated nanoparticles as a diabetic wound dressing. *Drug Dev. Ind. Pharm.* 42(5):707-719. doi:10.3109/03639045.2015.1075030.
- Haycocks S, Chadwick P, Guttormsen K (2011). Use of a DACC-coated antimicrobial dressing in people with diabetes and a history of foot ulceration. *Wounds UK.* 7(1):108-114.
- Kanchanasamut W, Pensri P (2017). Effects of weight-bearing exercise on a mini-trampoline on foot mobility, plantar pressure and sensation of diabetic neuropathic feet; a preliminary study. *Diabet. Foot Ankle.* 8(1):1287239. doi:10.1080/2000625X.2017.1287239.
- Kim BYS, Rutka JT, Chan WCW (2010). Nanomedicine. *N. Engl. J. Med.* 363(25):2434-2443. doi:10.1056/NEJMra0912273.
- Limb DL, Surgery P, Vidyapeetham AV, Limb DL, Surgery P (2013). Revascularization in the diabetic lower limb «J. Diabet. Foot Complications. 5 (1)18-23. <http://jdfc.org/2013/volume-5-issue-1/revascularization-in-the-diabetic-lower-limb/>.
- López T, Rodríguez CE (2015). Uso de la nanopartícula de de úlceras en pie diabético: comunicación preliminar. *Rev. la Fac Med la UNAM.* 58:5-12.
- Moura LIF, Dias AMA, Carvalho E, De Sousa HC (2013). Recent advances on the development of wound dressings for diabetic foot ulcer treatment - A review. *Acta Biomater.* 9(7):7093-7114. doi:10.1016/j.actbio.2013.03.033.
- Nacionales R (2012). Encuesta Nacional de Salud y Nutrición. CDMX.
- O'Loughlin A, McIntosh C, Dinneen SF, O'Brien T (2010). Review Paper: Basic Concepts to Novel Therapies: A Review of the Diabetic Foot. *Int. J. Low Extrem Wounds.* 9(2):90-102. doi:10.1177/1534734610371600.
- Pemayun TGD, Naibaho RM (2017). Clinical profile and outcome of diabetic foot ulcer, a view from tertiary care hospital in Semarang, Indonesia. *Diabet Foot Ankle.* 8(1):1312974. doi:10.1080/2000625X.2017.1312974.
- Piao Y, Burns A, Kim J, Wiesner U, Hyeon T (2008). Designed fabrication of silica-based nanostructured particle systems for nanomedicine applications. *Adv. Funct. Mater.* 18(23):3745-3758. doi:10.1002/adfm.200800731.
- Practice IB (2013). Best practice guidelines : Wound Management in Diabetic Foot Ulcers.
- Rao S, Pallela N, Narahari P (2017). Comparison of negative pressure wound therapy with moist wound therapy in the treatment of diabetic foot ulcers with non- revascularisable peripheral vascular disease. 4(7):1-4.
- Ruiz, Parizzi, Pezzotto P (2013). Estudio de casos y controles. Métodos Investig. clínica y epidemiológica. 81(2):131-137. doi:10.1016/B978-84-8174-709-6.50008-7.
- Sandri G, Bonferoni MC, D'Autilia F, et al (2013). Wound dressings based on silver sulfadiazine solid lipid nanoparticles for tissue repairing. *Eur. J. Pharm. Biopharm.* 84(1):84-90. doi:10.1016/j.ejpb.2012.11.022.
- Smith BR, Gambhir SS (2017). Nanomaterials for in Vivo Imaging. *Chem. Rev.* 117(3):901-986. doi:10.1021/acs.chemrev.6b00073.
- Surgeons AA of O (2012). Pie diabético. 56:47-52. <http://orthoinfo.aaos.org/topic.cfm?topic=A00683>.
- Tarride JE, Hopkins R, Blackhouse G, et al (2010). A Review of Methods Used in Long-Term Cost-Effectiveness Models of Diabetes Mellitus Treatment. *Pharmacoeconomics.* 28(4):255-277. doi:10.2165/11531590-000000000-00000.
- Vásquez-garcía R (2015). Perfiles clínico y epidemiológico de los pacientes con pie diabético Clinical and epidemiological profiles of patients with diabetic foot. pp. 294-301.
- Volmer-Thole M, Lobmann R (2016). Neuropathy and diabetic foot syndrome. *Int. J. Mol. Sci.* 17(6). doi:10.3390/ijms17060917.